

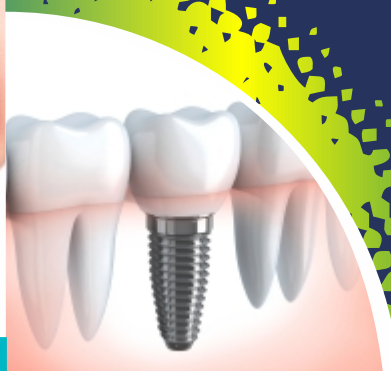

www.idakochi.org

JIDAK

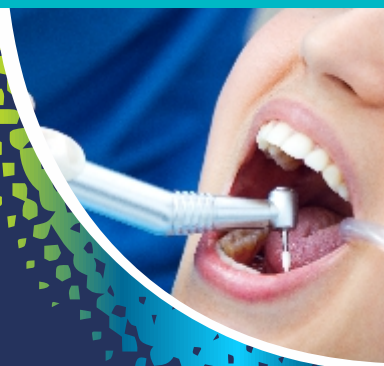Jul.- Sep. 2022, Volume 4, Issue 3

JOURNAL OF INDIAN DENTAL ASSOCIATION - KOCHI



INDIAN DENTAL ASSOCIATION

KOCHI BRANCH





www.idakochi.org

JIDAK

Jul.- Sep. 2022, Volume 4, Issue 3

JOURNAL OF INDIAN DENTAL ASSOCIATION - KOCHI

Journal of Indian Association of Kochi Branch (JIDAK) is the official scientific publication of Indian Dental Association, Kochi Branch. It is a peer-reviewed journal published quarterly in e-format as well as print format.

The journal invites manuscripts from dental and other allied health sciences. It publishes manuscripts under categories of Original Research, Review and Case Reports.

{ For submission of manuscripts,
log on to www.jidakochi.org.
For communications,
mail to jidakochi@gmail.com. }

EDITORIAL BOARD

Co-editors

Dr Niveditha B
Dr Noorudeen A M
Dr Bobby Antony Cyriac
Dr Binila S Babu
Dr Pooja Latti
Dr Seema George
Dr Nithin Thomas
Dr Latha P Rao
Dr Bhat Sangeetha Govinda

Chief Editor

Dr Vidhya Parameswaran

Advisory Board

Dr V I Paul
Dr George P John
Dr Vinod Mathew
Dr Sunil Mathew
Dr Nevin Thomas

Chief Editor's Message

Dear Friends

Welcome to the third issue of the year 2022. It's been the fourth year for this journal. Started in 2019, JIDAK has been publishing only scientific articles with excellent clinical content. This is to serve its benefits to practitioners as well as academicians.

As we release this issue, I highly urge more practitioners to share their experiences with us in the form of case reports, case series, original research etc. Experience is the best teacher and the worst experiences teach us the best lessons.

In today's world, where the demand and supply does not seem favorable for our profession, it is indeed a fact that only the survival of the fittest happens. Hence it is also important to share your valuable experiences, innovative techniques not forgetting the basics... to the newer generations.

Also, it's a true fact that you learn better when you teach someone.

Hoping for good responses in the upcoming issues, I thank my editorial team, authors and reviewers to help me publish this issue on time.

Thanks, and happy reading!!!



Dr Vidhya Parameswaran
Chief Editor- JIDAK
IDA Kochi

CONTENTS

TRACKING A BITE: A REVIEW

Dr. Vinitha Alex

04-09

CARIES RISK ASSESSMENT: AN OVERVIEW

Anuva Bhardwaj, Indumathi K P
Meenakshi Chopra, Shilpa Pahal
Talika Jasuja, Meenu Godara

10-18

SURFACE TREATMENT OF INDIRECT RESTORATIONS - A REVIEW

Abijith R S, Leelu J Puthumana, Prasanth Dhanapal
Mohammed Sagir, Biju P Babu, Kennet J Chirayath

19-23

CONSERVATIVE BRIDGES - AN UNEXPLORED TREATMENT OPTION

Jewel Mary Jose, Prasanth Dhanapal,
Mohammed Sagir, Biju P Babu, Jojo Kottoor
Jayakanth K

24-28

NON-VITAL BLEACHING TECHNIQUE OF DISCOLOURED TOOTH: A NARRATIVE REVIEW

Akthar Ramees M K, Prasanth Dhanapal,
Mohammed Sagir, Kennet J Chirayath
S Maneesh Ahamed, Kripa T

29-34

TRACKING A BITE: A REVIEW

ABSTRACT

Forensic Dentistry is the branch of dentistry which delineates the overlap between dental and legal professions. A Pediatric dentist plays an important role in forensic dentistry by applying his expertise in various fields such as child abuse and neglect, age determination, dental records, accidental or non-accidental oral trauma, and mass disasters by examination of the teeth and jaws structure for clues. These dental findings may be helpful in forensic identification wherein an unidentified individual can be identified. Lip prints and palatal rugae patterns can help in a person's identification. Teeth can also help in determining gender of the skeletonized remains using dental DNA. Forensic dentistry plays an important role in crime investigation in injury caused by dentition, such as bite marks. The aim of this article is to discuss the role of a pediatric dentist in various aspects of forensic dentistry/odontology and various procedures needed for examination, identification, and investigations.

KEYWORDS

Age estimation, bite marks, forensic dentistry, forensic identification, pediatric dentist role.

Authors:

Dr. Vinitha Alex

Consultant Pediatric Dentist
Swiss Dental Care
Kadavanthra

Email id: vinithabenjith@gmail.com
Contact number: 8281189996

J Ind Dent Assoc Kochi 2022;4(3):4-9.

INTRODUCTION

Forensis in Latin means before the forum (a place where legal matters are discussed).¹ Forensic Dentistry is defined as a branch of dentistry which, in the interest of justice, deals with the proper handling and examination of dental evidence, and with proper evaluation and representation of dental findings.² The father of forensic odontology Dr. Oscar Amoedo wrote first dissertation entitled *L'Art Dentaire en Legale* in 1898 which is considered as the first comprehensive book on forensic odontology.³ Currently forensic dentistry/odontology has evolved as a separate specialty which relies on the knowledge of teeth and jaws, dental anatomy, and histology, radiography, pathology, dental materials, and various developmental anomalies. Forensic identification is a multidisciplinary team work that involves experts from law enforcement officials, criminalists, serologists, forensic anthropologists, forensic dentists, forensic pathologists, and other specialists, who help in establishing deceased identity, cause of death, factors contributing to death, and the time of death.²

Role of a Pediatric Dentist

Using both physical and biological dental evidence, a Forensic dentist can identify human remains and bite marks. A pediatric dentist can play an important role in the identification of the bite marks. Dental trauma is a very common finding in children which is caused due to sports, accidents, or any abuse. A pediatric dentist can help in the investigations of legal officers by implementing his/her expertise in recognition of signs and symptoms of child abuse and identification of such victims. Also a pediatric dentist can contribute information to physicians about oral and dental manifestations of child abuse and neglect.² Pediatric dentist is also concerned with the maintenance of antemortem records which may be useful in dental identification later.

Proper recording of dental findings is an important step in management of the dental records. As a child undergoes continuous physiological changes, each and every finding should be recorded in detail. The dental record is a valuable legal document owned by the dentist. All the entries must be signed by the

recording personnel. Any changes in the record should not be erased at any cost. Else it should be corrected with a single line drawn through the incorrect material, so that the original entry will remain readable.⁴ Dental records of a child patient has to be retained until he/she reaches the age of maturity. For adults, the record is usually kept for 7-10 years. Various dental records include different clinical tests, laboratory tests, prosthesis, study models, radiographs and photographs.⁵

Dental Identification

Teeth are considered as one of the most indestructible structures and are usually resistant to postmortem decomposition. Human dentition is never ever similar in any two individuals. Morphology and arrangement vary in every person.¹ Hence teeth are considered to be more unique. This uniqueness make it a cornerstone in positive identification of living or deceased individual.² Dental impressions serve as an invaluable tool as they are found to be more unique than DNA. Similar kind of genetic makeup may be shared by identical twins, but their dental impressions differ.⁶ Furthermore, most of the materials used in dentistry seems to be resistant to postmortem decomposition. Hence dental evidence is very much helpful in identifying badly burned, traumatized, decomposed, or any skeletonized remains in mass disasters.¹

Comparative identification

The postmortem dental remains are usually compared to the antemortem dental records to confirm the identity of the suspected individual. In children below 5 years of age, nil or minimal comparable data is available due to less number of filled/restored teeth and very few radiographic indications. Normal maturational changes in the growing period will alter the dental records. If the child has reached the age of 5-6 years, bitewing radiographs always act as a part of dental record even if there is absence of any filling/restoration or treatment needed is low.² Oral autopsies are done to remove tongue and contents of the floor of mouth in a tunneling fashion to obtain postmortem radiographs or records in comparative identification. Separate postmortem and antemortem units act as a part of this identification team.¹

Reconstructive identification/ Dental Profiling

When virtually no clue exists for the identification of the deceased, dental profiling is done to elicit ethnicity, race, sex, and age of the dead individual.

Ethnicity

Various nonmetric characteristics such as Carabelli's trait, shovelling, three cusped maxillary second molar, four cusped mandibular molars and mandibular molar groove pattern may help in finding the ethnic origin of the deceased depending on the presence or absence of the above mentioned features. Different features have to be considered together while concluding an ethnic origin.¹

Sex determination

Various methods are used for sex determination using teeth which includes visual/clinical method, microscopic method and advanced method.

Visual/clinical method: In young adults, buccolingual and mesiodistal dimensions of teeth are found to be helpful in sex determination. Among teeth greatest sexual dimorphism is exhibited by canines as it is less carious and highly resistant to postmortem changes. 86% of success rate in sex determination has been observed with Mandibular canine index (MCI), which is measured by calculating the ratio between mesiodistal mandibular canine crown width and intercanine width. The standard MCI value is 0.274. Higher MCI value indicates male and lower value indicates female.¹

Microscopic method: Barr bodies are inactive X chromosome found in female somatic cell. They can remain in a dehydrated pulp for 1 year. When heated up to 100°C for 1 hour, these Barr bodies can show sexual diagnostic features. DNA analysis done to find out the presence or absence of Y chromatin is a definitive method for determining sex.¹

Advance methods include use of AMEL gene and polymerase chain reaction (PCR).

AMEL gene codes for a major matrix protein secreted by ameloblasts called amelogenin.

AMEL gene is located on both X and Y chromosomes. Females will show two identical AMEL genes while males will show two genes which are not identical. DNA amplification done by PCR yields 100% success in sex determination.¹

Age estimation

Skeletal/craniofacial structures such as long bones, closure of fontanelle/sutures, and ossification of hand-wrist bones, and mandibular features can be used in age estimation. Age assessment in prenatal, neonatal, and early postnatal period can be very accurate as different events are like tooth-bud formation, completion of formation of primary teeth enamel and formation of permanent first molar. The indicator of birth, neonatal line indicates a live birth. Hence it has got legal implications in foeticide and infanticide.¹

Tooth eruption and tooth calcification are important events in age estimation in case of children and adolescents. It is a convenient clinical method. It can be assessed both visually and radiographically. Modified Demirjian's method uses the development of teeth divided into ten stages each.³

A regression formula was formulated by Acharya for the age determination in Indian children. The formula is given below.

Male age = $27.4351 - (0.0097 \times S2) + (0.000089 \times S3)$

Female age = $23.7288 - (0.0088 \times S2) + (0.000085 \times S3)$

Gustafson's method is used for age determination in adults. The method includes assessment of various events namely attrition (A), secondary dentin deposition (S), loss of periodontal attachment (P), cementum apposition at the root apex (C), root resorption at the apex (R), and dentine translucency (T). Incremental lines in acellular cementum are used in age estimation. Hypomineralized bands in the incremental line indicate pregnancy, skeletal trauma, and renal disorders which can be related to person's life history, facilitating identification. Mineralized unstained cross-sections of teeth are used.¹

Amino acid racemization is a biochemical indicator in age estimation. Aspartic acid has got a rapid rate of racemization (high in root

dentin). With increase in age aspartic acid spontaneously gets converted from L-type to D-type. Hence, at different ages there seems to have a constant change in the ratio of L-and D-aspartic acid which is used for the age estimation. Both incremental lines and aminoacid racemization estimates age within ± 3 years of actual age.

Dental DNA for Identification

More than fingerprints, scars, and facial appearance DNA has got a greater chance of survival. It acts as a basis of all blood group types, red cell antigens, and protein isoenzymes. Teeth serve as an excellent source of DNA. Rich sources of DNA include odontoblasts, peripheral nerves, fibroblasts, undifferentiated mesenchymal cells, endothelial cells, and nucleated components of blood in pulpal soft tissue. By tooth sectioning, tooth crushing, or cryogenic grinding technique, dental DNA can be made use in identification of suspected individuals.⁷

Palatal Rugae Pattern

"Palatal Rugoscopy" is an ideal parameter for identification as rugae usually do not undergo any change except in length. Rugae shows resistance to decomposition to an extent. They keep the same position throughout the life of an individual. It reappears even after trauma or surgery. Hence palatal rugae pattern is unique to every single person.⁸

Lip Prints

Lip prints obtained from an individual are permanent and unchangeable. Study of lip prints is known as Cheiloscopy. From the 6th week of intrauterine life identification of lip pattern is possible. So these patterns can act as an important evidence left at the crime scene. Any major trauma to lips result in scarring and also surgical treatment affects the size and shape of lips. Depending on the pressure applied or direction of pressure application, lip prints differ in their appearance.⁸

Bite Marks

Application of Forensic odontology in crime investigation includes identification of bite

marks caused by dentition. Bite marks are often associated with child abuse, violent fights, sex crimes, sporting events and sometimes self-inflicted too.⁹ A Pediatric dentist should be able to meticulously observe and document bite marks. He/she should have thorough knowledge about such findings and their significance. Bite marks can be found on an injured tissue or an inanimate material such as foodstuffs and can accurately depict the unique pattern of the biter's teeth.¹⁰

Initially, bite marks appear as indentations due to the pressure applied by teeth. But these indentations will soon disappear due to elasticity of skin and later edema occurs over the bitten area. Which obscures the bite marks completely. When this edema subsides subcutaneous bleeding is seen as contusions or bruises. Lacerations can be seen when the bite intensity is more. The most extreme form is avulsion where a part of a tissue is bitten off.¹

Milk teeth bite marks consists of smaller, rounded, bow-like arches and spacing between them. Generally bite marks appear as circular/elliptical with a central ecchymosis. Classical features/appearance of bite marks for incisors (rectangular marks), canines (triangular/rectangular), premolars and molars (spherical/point) differ from each other. Individual characteristics such as fractures, rotations, crowding and spacing are also very helpful in identification of the suspect. A classical bite mark presents as oval or circular mark consisting of two opposing arcades, separated by a small open space at their bases with a diameter of 25–40 mm. Central bruising with clear tooth marks, and individual dental characteristics give a strong evidentiary value.⁹

Following confirmation of the injury a bite mark investigation should be done. Bite mark investigation include collection of evidence from the victim and records from the suspect. Dental record of the bite mark includes photography, impression, models, and saliva swab collection. Photographs should be taken first as it should not affect any other records such as impressions and taking swabs.¹¹ Two types of photographs have to be taken, one for an orientation and the other a close-up view. Photographs should be taken for 3 consecutive days for documentations.¹⁰ Polyvinyl Siloxane impression is used to record the bite mark immediately after swabbing it.² Recognition of any uncommon features of bite mark helps in accurate identification.

Inter canine distance method is usually recorded to recognize primary dentition and permanent dentition. Distance <30mm belongs to a child and a distance above 30 mm belongs to an adult.⁹ Other methods used include odontometric triangle method and comparison technique. Odontometric triangle method is an objective method. In this method a triangle is made by marking three points A, B, and C on the bite mark tracings and teeth models. Point A and point B are marked on the outermost convex points on the canines and centre of the two central incisors is marked as point C. These three points are joined to form a triangle ABC. The lines AB, BC, and CA are measured, and corresponding angles a, b and c are also calculated. This is done in both upper and lower casts. The values obtained are compared with the bite marks on wax, apple or skin. Data analysis is done statistically and the results are obtained.^{12,13,14}

In comparison method comparison of bite mark measurements are made with suspect's impression models. Direct comparison is done by placing suspect's model on the bite mark whereas in indirect method suspect's model is traced onto clear acetate and compared with the photographs taken.¹¹ nowadays computer software programs have been developed which can be used for comparison.^{1,15}

In odontometric triangle method (objective method), a triangle is made on the tracing of bite marks and teeth models by marking three points A, B, and C. Points A and B are plotted on outermost convex points on the canine teeth.

Center of two central incisors is selected as Point C. All three points are joined to form triangle ABC. Lines AB, BC, and CA are measured, and angles a, b, and c are calculated. This is done for both upper and lower jaw teeth model and compared with that of bite marks of wax, apple, and skin. Statistical analysis is carried out, and results are obtained.

CONCLUSION

Wide variations exist in size, shape, structure, form, cusp locations/projections of teeth, and in facial profile and chin relations which is unique to every individual. This uniqueness of dental records help in identification. A pediatric dentist can play an important role in bite marks analysis, injuries, and child abuse and proper management, examination,

evaluation and preservation of child dental evidence in criminal or civil legal proceedings in the interest of justice.

REFERENCES

1. Ashith BA, Sivapathasundharam B. Forensic Odontology. Shafer's Textbook of Oral Pathology. 6th ed. New Delhi: Elsevier; 2009. p. 871-97.
2. Vinutha YJ, Krishnapriya V, Shilpa G, Vasanti D. Forensic dentistry: A pedodontist's perspective. J Med Radiol Pathol Surg 2015;1:8-14.
3. Brumit PC, Stimson PG. History of forensic dentistry. In: Senn DR, Stimson PG, editors. Forensic Dentistry. 2nd ed. Boca Raton: CRC Press; 2010. p. 17-8.
4. Avon SL. Forensic odontology: The roles and responsibilities of the dentist. J Can Dent Assoc 2004;70:453-8.
5. Gupta S, Agnihotri A, Chandra A, Gupta OP. Contemporary practice in forensic odontology. J Oral Maxillofac Pathol 2014;18:244-50.
6. Hemant M, Pandey A. Forensic Odontology and its applications. In: Jain N, editor. Textbook of Forensic Odontology. India: Jaypee Brothers Medical Publishers; 2013. p. 10-42.
7. Sweet D, Hildebrand D, Phillips D. Identification of a skeleton using DNA from teeth and a PAP smear. J Forensic Sci 1999;44:630-3.
8. Atreja G. Cheiloscopy and palatoscopy. In: Jain N, editor. Textbook of Forensic Odontology. India: Jaypee Brothers Medical Publishers; 2013. p. 155-68.
9. Stavrianos C, Tatsis D, Stavrianou P, Karamouzi A, Mihail G, Mihailidou D. Inter canine distance as a recognition method of bite marks induced at cases of child abuse. Res J Biol Sci 2011;6:25-9.
10. American Academy of Pediatric Dentistry. Guideline on oral and dental aspects of child abuse and neglect. Pediatr Dent 2014;36:167-70.
11. Sharma G, Yadav D, Singh H, Aggarwal AD, Sandhu R. Bite mark analysis-an

- important tool in crime investigation. J Indian Acad Forensic Med 2006;28:971-3.
12. Modak R, Tamgadge S, Mhapuskar A, Hebbale M, Vijayarabhavan NV. Bite mark analysis: Chasing the bite!. Indian J Oral Health Res 2016;2:61-6.
 13. Chhatpar S, Sabane VS. Role of bite mark analysis in identification of a person in forensic odontology. J Indian Dent Assoc 1989;60:173-9.
 14. Singh M, Das R, Rao KT. Bite marks an index for identification in crime (An experimental clinico-anthropological study). J Indian Acad Forensic Med 1988;10:21-5.
 15. Dongre PJ, Patil RU, Patil SS. Applications of forensic odontology in pediatric dentistry: A brief communication. J Dent Allied Sci 2017;6:17-21.

CARIES RISK ASSESSMENT: AN OVERVIEW

ABSTRACT

Currently, there have been many changes in understanding of the multifaceted nature of caries process and its management. Caries Management by Risk Assessment (CAMBRA) which is an evidence-based approach focuses on determining many factors causing the expression of disease and take corrective action. The clinicians can ascertain what behaviors are increasing a patient's risk for disease and disease progression by evaluating the current caries risk of a patient. With this modern CAMBRA protocol, a novel treatment plan can be designed to arrest dental caries thereby decreasing the chance of cavitation.. This review focuses on the repair of hard tooth tissues using noninvasive strategies.

Keywords: Caries management, Risk assessment, Lesion activity, Resin infiltrant.

Author:

Anuva Bhardwaj^{1*}

Indumathi K.P.²

Meenakshi Chopra³

Shilpa Pahal⁴

Talika Jasuja⁵

Meenu Godara⁶

¹Senior Lecturer

Department of Pedodontics

Rayat Bahra Dental College and Hospital

Mohali, Punjab

²Senior Lecturer

Department of Public Health Dentistry

SRM Kattankulathur Dental College and Hospital

SRM Institute of Science and Technology

Chengalpattu, Tamil Nadu, India

³Associate Professor

Department of Public Health Dentistry

SGT Dental College

Hospital and Research Institute

Gurugram, Haryana

⁴Consultant Dental Surgeon

Charkhi Dadri, Haryana

⁵Consultant Dental Surgeon

Sirsa, Haryana

⁶PG Student

Department of Conservative Dentistry and Endodontics

Faculty of Dental Sciences

PDM University, Bahadurgarh, Haryana

Corresponding Author:

Dr. Anuva Bhardwaj

Senior Lecturer

Department of Pedodontics

Rayat Bahra Dental College and Hospital

Mohali, Punjab

Mob.No: +91-98161-76155

Email: bhardwajanuva1@gmail.com

J Ind Dent Assoc Kochi 2022;4(3):10-8.

INTRODUCTION

Caries risk assessment is the determination of the likelihood of the incidence of caries (ie, the number of new cavitated or incipient lesions) during a certain time period.¹ It also involves the probability that there will be a change in the size or activity of the lesion in the mouth. When caries risk procedure is applied to populations it is termed as caries prediction.²

Caries activity tests estimate the actual state of disease activity (progression/regression). It is carried out in order to decide and monitor correct and efficient treatment of a patient.³

Caries Imbalance⁴

Disease indicators: White spots, Restorations >3 years, Enamel lesions and Cavities/ dentin.

Risk Factors: Bad bacteria, Absence of saliva and Dietary habits (poor).

Protective factors: Saliva & sealants, Antibacterial, Fluorides and Effective diet.

DISCUSSION

Concept of risk assessment

Term risk is often used to express the probability that a particular outcome will occur following a particular exposure usually implying a bad outcome. Estimations are made when the risk lies somewhere between 0 and 100%. In Dental Public Health, the concept of measuring and assessing risk which means confronting the varying susceptibilities to oral diseases has arrived more recently.⁵ The decline in caries experience at population levels that made it evident that not all children get caries, some do not get it, some get it only to a minor degree while others suffer badly from it. So the natural question of why do some get the disease and others do not has brought the concept of risk into caries prediction.⁶

OBJECTIVES⁶

- To improve the oral health in children, adolescents and adults.
- Introduce causal measures before irreversible lesions have become established.
- Introduce causal measures before irreversible lesions have become established.

Uses of caries risk assessment⁷

- Evaluate the degree of patient's risk of developing caries to determine the intensity of treatment.
- Help identify main etiologic agents to determine the type of treatment.
- Determine if additional diagnostic procedures are required - salivary flow rate analysis, diet analysis.
- Improve the reliability of the prognosis of the planned treatments.
- Assess the efficacy of proposed management and preventive treatment plan at recall visits.

Caries Risk Assessment Tools

Caries Risk Assessment Tool (CAT): This tool was developed by the American Academy of Paediatric Dentistry (AAPD) in 2006. Depending on the age of children CAT incorporates three factors in assessing caries risk i.e. Biological factors, Protective factors and Clinical findings.⁸

Factors^{9,10}

Biological

Patient with: Low socioeconomic status, >3 between meal sugar-containing snacks or beverages per day, Special health care needs, Recent immigrant.

Protective

Patient receives optimally-fluoridated drinking water, Brushes teeth daily with fluoridated toothpaste, Topical fluoride from health professional, Regular dental care.

Clinical Findings

Patient has >1 interproximal lesions, Active white spot lesions or enamel defects, Low salivary flow, Defective restorations, Wearing an intraoral appliance.

Caries risk assessment methods¹

- Caries questionnaire in combination with clinical examination
- AAPD'S caries risk assessment form

- Cariogram model
- CARE-Caries Assessment and Risk Evaluation Test
- CAMBRA- Caries Management By Risk Assessment
- TLM-Traffic Light Matrix

Cariogram^{11,12}

Cariogram is a new way in which to illustrate the interaction between caries related factors. This educational interactive program has been developed for better understanding of the multifactorial aspects of dental caries and to act as a guide in the attempts to estimate the caries risk. Original cariogram pie chart-3 colored sector:

- Red-bacteria
- Blue-sugar
- Light blue-host susceptibility

Later modified by including 2 more sectors:

- Yellow-circumstances
- Green-actual chances to avoid new cavities

Bacteria

- ü Type and amount of bacteria, bacterial adhesion, plaque formation rate, acid producing capacity and all factors which make plaque more or less cariogenic.

Diet

- Contents of fermentable carbohydrates and frequency of food consumption are included as well as possible antibacterial components in the food.

Susceptibility

- ü Remineralization of teeth, fluorides, saliva secretion and buffering capacity, salivary antibodies and salivary host components affecting demineralization and remineralization.

Care-caries assessment & evaluation test¹³

Many studies had shown the significance of genetics in caries development. Important in developed societies where a good dental

coverage, adequate fluoride exposure and where gross malnutrition and oral health are rare. This plays a vital role in assessing child's overall caries risk status. Researchers at the division of diagnostic sciences of the university of southern California school of Dentistry developed a novel salivary test for Genetic CRA-CARETEST.

CARE TEST- Only test that promote caries prevention at primary level. The widespread incorporation of CARE Test in clinical practice-future of dental care.

Caries Management by Risk Assessment (CAMBRA)¹⁴

The CAMBRA philosophy was first introduced nearly a decade ago when an unofficial group called the Western CAMBRA Coalition was formed that included stakeholders from education, research, industry, governmental agencies and private practitioners based in the western region of the United States. Evidence-based approach to preventing or treating the cause of dental caries at the earliest stages rather than waiting for irreversible damage to the teeth. Essentially based on the same factors as CAT to assess caries risk.

Traffic Light Matrix (TLM)¹⁵

TLM is based on 19 criteria in 5 different categories including saliva (6 criteria), plaque (3 criteria), diet (2 criteria), fluoride exposure (3 criteria) and modifying factors (5 criteria). Traffic light colours convey varying risk levels (red=high, yellow=moderate and green=low). The objective is to alert the clinician regarding the current risk status. This color code model keeps the visual interpretation simple and communicable to the patient as well.

Depending on predetermined criteria system scores Red, yellow & green light for each risk factors. Tests are carried for each risk factors independently and scores are generated.

The scores are compared with predetermined criteria. based on these criteria

Red for- high risk

yellow for- moderate risk

green for- low risk

Caries Risk Factors¹

- Plaque
- Specific microbes and caries risk

- Diet
- Saliva
- Eating pattern
- Immune system
- Inherited risk susceptibility

Plaque^{16,17,18}

It is important to estimate the number of surfaces affected, the amount of plaque accumulated, age of the plaque, whether its presence is associated with carious lesions in those same sites.

Risk areas for plaque accumulation

Mesiolingual and distolingual mandibular surfaces of molars, Mesio Buccal and distobuccal surfaces of maxillary and mandibular molars.

Plaque formation rate

On specific tooth surfaces thick plaque is present with a high percentage of acidogenic and aciduric bacteria - remains too long. Rationale for the development of Plaque formation rate index by Axelsson (1984,1989, 1991) based on the amount of plaque freely accumulated (de novo) 24 hours. High plaque formation rate when associated with inadequate salivary secretion is considered to be at risk.

Nature of Plaque

A high intake of fermentable carbohydrates particularly sucrose will result in a sticky plaque rich in polysaccharides and an increased plaque formation rate. In the prevention plan for individuals with PFRI score of 4 or 5 and a frequent intake of sugar containing products should emphasize not only on frequent plaque control but also reduction in frequency of sugar intake.

Thickness and Age of the plaque

An increasing mass of plaque impedes penetration by saliva to protect the enamel. The critical fall in pH (below 5) occurs only in three day old plaque. In a tooth brushing population such plaque would be found if at all only on the approximal surfaces of molars and premolars and sub-gingivally.

pH of plaque

Pits and fissures favor plaque acidity compared to other tooth surfaces. The plaque on the

maxillary incisors is less alkaline than mandibular plaque hence favoring the development of caries. Mandibular plaque pH has less pronounced pH response than maxillary plaque, the lowest values are recorded for anterior sites.

Plaque minerals

Calcium and Phosphates concentrations remain stable hence plaque concentrations can be considered as risk factors for caries. Fluoride concentrations is better considered as a risk indicator as relationship with caries has not been reported in longitudinal studies.

Specific microbes and caries risk^{19,20,21}

Mutans streptococci and Lactobacilli have historically captured the greatest interest among researchers and clinicians. A high count in saliva more than 1 million colony forming units per ml of saliva indicates that most teeth are colonized by bacteria i.e. many tooth surfaces are subject to increased risk. The accuracy of salivary tests for Mutans streptococci in predicting future caries in the whole population is less than 50%. In populations with low caries prevalence, the caries predictive ability of microbiological tests is even lower. Tests for Lactobacilli are less sensitive for predicting caries than are those for MS.

Rationale for combining salivary ms tests and pfri for prediction of caries risk

Combination of salivary S mutans counts and plaque formation rate index (PFRI scores 1-5) is recommended for caries risk prediction, according to,

- No caries risk: Streptococcus mutans-negative individuals
- Low caries risk: Streptococcus mutans-positive individual with a PFRI score of 1 or 2
- Moderate Caries risk: Streptococcus mutans-positive individual with a PFRI score of 3
- High caries risk: Individuals with high S mutans counts and a PFRI score of 4 or 5.

Lactobacilli

Lactobacilli are highly influenced by dietary carbohydrate content and intake frequency. Persistently high levels of lactobacilli after elimination of retentive sites like cavitated lesions indicate a diet rich in carbohydrates.

Other Bacteria

Many 'low pH non mutans Streptococci' which included *S. gordonii*, *S. oralis*, *S. mitis*, *S. anginosus* outnumber the MS in plaque samples. Polymicrobial analysis have shown *Actinomyces* species predominate in active as well as arrested root surface lesions, suggesting a polymicrobial etiology for caries initiation in root surfaces.

Regular microbiological tests made by the dentists on an individual can be seen as monitors of change in the ecology of the oral cavity rather than caries indicators, indicating deviation from the norm for that individual. So any deviation from established colonial pattern of oral bacterial species would represent a change which if persisted could indicate a significant variation in the oral environment. Thus available bacterial tests should be used to determine cariogenic bacteria in the mouth and motivate behavioral changes, monitoring therapies like chlorhexidine therapy.

Diet²²

Diet rich in fermentable carbohydrates (frequent sugar intake) is a very powerful external risk factor and prognostic risk factor for dental caries in populations with poor oral hygiene habits and associated lack of regular topical fluoride exposure from tooth pastes.

Eating Pattern²²

Fall in plaque pH after consumption of sugary foods may be modified by the consumption of less fermentable foods before, concurrently or afterward e.g.: cheese.

Saliva²²

Saliva plays an important role in the health of soft and hard tissues in the oral cavity.

Demineralization and Remineralization²³

Main factors governing stability of enamel are the pH and concentration of Ca, PO₄³⁻, and F in solution which are all derived from saliva. The role of saliva in this process is highly dependent on accessibility, which is closely related to thickness of plaque. The ability of saliva to remineralize demineralized enamel crystals stems from its ability to supply bioavailable calcium and phosphate ions to the tooth. At physiological pH, unstimulated and stimulated parotid, submandibular and whole saliva are supersaturated with respect to most solid calcium phases.

Immune system and Caries risk²⁴

Salivary immunoglobulin are mucosal antibodies that act as the first line of defense, and they include two major antibodies, namely, secretory IgA and IgG. Higher caries prevalence in preschool children with higher level of microbes such as mutans streptococci, *C. albicans* and *Prevotella* spp., salivary protein including IgA, IgG immunoglobulins, histatin peptides, in saliva compared with caries free individuals.

Caries Risk Indicators²⁵

Caries risk indicators broadly divided into: Pathological factors and Protective factors

Pathological factors are-

- 1- Past caries experience
- 2- Dietary habits
- 3- Socioeconomic status
- 4- Fluoride exposure
- 5- Medical factors

Past Caries Experience²⁵

Most powerful single predictor for future caries incidence in children and young adults. It represents the sum result of all the etiologic and modifying risk factors to which individuals have been exposed. This is criticized because the aim should be to determine the high risk individuals before there are any signs of past caries experience.

Key-risk age group 1: Ages 1 to 2 years²⁶

Kohler et al (1978,1982) showed that mothers with high salivary MS levels frequently transmit MS to their babies as soon as the first primary teeth erupt, leading to greater development of caries. It was also shown that the practice of giving infants sugar containing drinks in nursing bottles at night increases the development of caries. Wendt and Birkhed, 1995

Key-risk age group 2: Ages 5 to 7 years²⁶.

In a study by Carvalho et al (1989), plaque reaccumulation was heavy on the occlusal surfaces of erupting maxillary and mandibular molars, particularly in the distal and central fossae.

Key-risk age group 3: Ages 11 to 14 years²⁶

Normally, the second molars start to erupt at the age of 11 to 11.5 years in girls and at around

the age of 12 years in boys. Total eruption time is 16- 18 months. During this period, the approximal surfaces of the newly erupted posterior teeth are most caries susceptible.

Key-risk age groups in young adults²⁶

Under certain circumstances, young adults (19 to 22 year olds) may also be regarded as a risk age group. Most have erupting or newly erupted third molars without full chewing function and with highly caries-susceptible fissures.

Other risk groups²⁶

- Persons who work in occupations where frequent food sampling is required
- Persons who are obese
- Persons who abuse recreational drugs
- Persons who have systemic diseases and are taking regular medication
- Women who are pregnant

Uses of Caries Risk Assessment²⁰

- Evaluate the degree of patient's risk of developing caries to determine the intensity of treatment.
- Help to identify main etiologic agents to determine the type of treatment.
- Help in determining whether additional diagnostic procedures are required: salivary flow rate analysis, diet analysis.
- Improve the reliability of the prognosis of the planned treatments
- Assess the efficacy of proposed management and preventive treatment plan at recall visits.

TESTS IN CRA²⁷

- Bacterial challenge: determination of Mutans streptococcus as an indicator of relative risk.
- Diet: determination of lactobacilli as an indicator of sugar content in diet.
- Remineralization potential: salivary flow rate and buffer capacity as an indicator of potential biologic repair.
- Host susceptibility: caries experience as an indicator of past activity.

Microbial tests for mutans streptococci detection^{28,29}

Several methods are available to measure the

levels of mutans streptococci in saliva and plaque and on individual tooth surfaces.

- Laboratory Method
- Chair side Method
- Survey Method
- Selective Method
- Adherence Method

Saliva is collected from the individual to be sampled. Then, mixed with proper transport medium. After incubation using a selective medium, mutans colonies on the plates are counted and the results are expressed as no. of colony forming per units per ml saliva. A common type of selective agar plate for mutans streptococci is the mitis salivarius bacitracin agar, MSB agar. For screening surveys using agar plates, a simplified method has been described in which wooden spatulas are contaminated by saliva and then directly pressed against selective agar plates. After incubation the no. of colonies on a predetermined area of the agar is calculated.

Strip Mutans method for Mutans Streptococci Counts³⁰

Dentocult-SM developed by Jensen and Brathall (1989). Useful for both chair side as well as for dental research. This method utilizes the ability of MS to grow on a hard surface in a selective mitis salivarius broth containing 20% sucrose. Has a specially rounded plastic strip for sampling which is slightly roughened on one side to promote bacterial adhesion. These strips can be stored for years in plastic foils for future comparisons. The density of the colonies is evaluated against a chart provided by the manufacturer and scored 0-3, where the scores 2 and 3 correspond to approximately 1×10^5 CFU and $>1 \times 10^6$ CFU/ml saliva.

Modification- Strip mutans technique³⁰

The sampling of the selected sites is carried out either with a wooden tooth pick or a small saline wetted brush and transferred straight across the strip on an elevated pad so that four sites can be sampled on each strip. It is useful for monitoring the outcome of a site specific antibacterial treatment.

Survey Method³¹

Plates can be placed into plastic bags

containing expired air, which are then sealed and incubated at 37° C. Counts of more than 100 CFU by this method are proportional to greater than 108 CFU of *S. mutans* per ml of saliva by conventional methods.

Selective Method³¹

Plaque samples are collected from gingival third of buccal tooth surface. Toothpicks are inserted into approximal spaces and Place into Ringer's solution. Contaminated sides are then pressed into the approximal spaces for Incubation at 37°C for 72 hours. Sites with or without mutans streptococci can be identified.

Adherence Method³¹

Unstimulated saliva is inoculated in MSB Broth. Inoculated tubes are set at 60° angle and incubated aerobically at 37°C for 24 hrs. After growth has been observed, the supernatant medium is removed.

Microbial tests for Lactobacilli count

Laboratory Method³²

Saliva is obtained by chewing a piece of paraffin. Shaken with glass beads to break up aggregates of bacteria. Saliva is then mixed with a buffer solution and 1 ml of the dilutions 10-2 and 10-3. 10ml is poured into the Petri dish. Plates are incubated at 37°C for 4 days. Lactobacilli appear as whitish dots.

Salivary Flow Rate³³

Can be done by paraffin wax or citric acid 3%. Saliva derived is divided by collection time i.e. 5 minutes or ml/minute. Adults have rates of 1-1.5 ml/ minute, values below 0.7ml/minute are low and indicate risk for caries.

In children the values depend on age and cooperation. Preschoolers have secretion rates of 0.5ml for stimulated and 0.3ml/min for unstimulated saliva. An unstimulated rate of 0.1ml/min is considered a risk value.

Buffering Capacity³⁴

Dentobuff method (Ericsson and Brathall, 1989)

Dentobuff strip is used. This method reflects the bicarbonate system and identifies saliva

with low (yellow), intermediate (green) and normal (blue) buffer capacity. Test should be read exactly after 5 minutes otherwise, color changes with time and will give misleading results. The yellow color indicates pH of 4 or less, meaning the saliva was unable to raise the pH and should be considered as a risk value.

Viscosity of Saliva³⁴

Measurement of oral mucosal friction by aid of rheologic device has been developed and may be important for elderly patients on xerogenic drugs.

Salivary Clearance Rate³⁵

Clearance of food and microorganisms is disturbed by either extensive growth of bacteria as a consequence of poor oral hygiene, excessive dietary intake of fermentable carbohydrates or systemic diseases or hyposalivation. In caries susceptible individuals usually a combination of these factors are responsible. Clearance rate is dependent on SSR and volume of saliva before and after swallowing. Thus a high SSR will result in rapid clearance and low SSR in a slow clearance. Caries risk increases enormously with low SSR.

Caries Activity Tests

Snyder Test³⁶

Saliva is collected before breakfast by chewing paraffin wax. A tube of Snyder glucose agar is melted and then cooled to 50°C. Saliva specimen is shaken vigorously for 3 minutes. 0.2ml of saliva is pipetted into the tube of agar and immediately mixed by rotating the tube. Agar is allowed to solidify in the tube and is incubated at 37°C. Color change of the indicator is observed after 24, 48 and 72 hours of incubation by comparison with an uninoculated tube against a white background.

Alban Test³⁶

60grams of Snyder test agar is placed in 1 liter of water. Suspension is brought to boil over a low flame. After suspension has melted the agar is distributed using about 5 ml per tube. Tubes should be autoclaved for 15 minutes; allowed to cool in refrigerator. 2 tubes are taken from the refrigerator and patient is asked to expectorate a small amount of saliva directly into the tubes. Tubes are labeled and incubated at 98.6°F for 4 days. Tubes are observed daily for color change.

Swab test³⁶

Advantage is no collection of swab is required. It is valuable in evaluating caries activity in very young children. Principle is same as Synder test. The oral flora is sampled by swabbing the buccal surface of teeth with cotton.

Reductase Test³⁶

This test measures the activity of reductase enzyme present in salivary bacteria. The sample is mixed with fixed amount of diazo-resorcinol. The changes in color after 15 minute is taken as a measure of caries activity.

CONCLUSION

Across age and circumstance indicators of past caries experience are the strongest predictors. Bacterial levels are included in the most accurate prediction models. The success of a caries risk assessment model, one or more social, behavioral, microbiologic, environmental or clinical variables should be included due to the multifactorial assessment of carious etiology. The multifactorial etiology of dental caries makes it likely that even the most sophisticated risk models will be of limited value in predicting future caries development very accurately.

REFERENCES

1. American Academy of Pediatric Dentistry. Caries-risk assessment and management for infants, children, and adolescents. The Reference Manual of Pediatric Dentistry. Chicago, Ill. American Academy of Pediatric Dentistry; 2021:252-7.
2. American Academy of Pediatric Dentistry. The use of a caries-risk assessment tool (CAT) for infants, children and adolescents. *Pediatr Dent* 2002;24(7):15-7.
3. Macey R, Walsh T, Riley P, Glenney AM, Worthington HV, Clarkson JE et al. Tests to detect and inform the diagnosis of caries. *Cochrane Database Syst Rev* 2018;12: CD013215.
4. Maheswari SU, Raja J, Kumar A, Seelan RG. Caries management by risk assessment: A review on current strategies for caries prevention and management. *J Pharm Bioallied Sci* 2015;7(Suppl 2): S320-S324.
5. Burt BA. Concepts of risk in dental public health. *Community Dent Oral Epidemiol* 2005; 33: 240-7.
6. Rothman KJ. *Epidemiology: an introduction*. New York: Oxford University Press; 2002.
7. Reich E, Lussi A, Newbrun E. Caries-risk assessment. *Int Dent J* 1999;49:15-26.
8. Guideline on caries risk assessment and management for infants, children and adolescents. *Am Acad Pediatr Dent* 2014;38(6): 142-49.
9. Ramos-Gomez FJ, Crall J, Gansky SA, Slayton RL, Featherstone JDB. Caries risk assessment appropriate for the age 1 visit (infants and toddlers). *J Calif Dent Assoc* 2007;35(10):687-702.
10. American Dental Association Councils on Scientific Affairs and Dental Practice. Caries Risk Assessment Form (Ages 0-6). American Dental Association: Chicago, Ill; 2008.
11. Bratthall D, Petersson GH. Cariogram a multifunctional risk assessment model for a multifactorial disease. *Community Dent Oral Epidemiol* 2005; 33: 256-64.
12. Petersson GH. Assessing caries risk-using the cariogram model. *Swed Dent J Suppl* 2003;(158):1-65.
13. Denny PC, Denny PA, Takashima J, Si Y, Navazesh M, Galligan JM. A novel saliva test for caries risk assessment. *J Calif Dent Assoc* 2006;34:287-90.
14. Featherstone JD, Domejean-Orliaguet S, Jenson L, Wolff M, Young DA. Caries risk assessment in practice for age 6 through adult. *J Calif Dent Assoc* 2007;35:703-7, 710-3.
15. Caries Risk Assessment for Children: Information for Oral Health Practitioners. Colgate Dental Education Programs, Special Topic No. 10; 2015.
16. Miller WD: *The Microorganisms of the Human Mouth*. The SS White Manufacturing Co. Philadelphia, 1890 .
17. NIDR: Oral Health of United States Adults. NIH Publ. No. 87-2868, 1987 .
18. Bowden GH. Dose assessment of microbial composition of plaque/saliva allow for diagnosis of disease activity of individuals? *Community Dent Oral Epidemiol* 1997;25: 76-81.
19. Mortazavi S, Akhlaghi N. Salivary

- Streptococcus mutans and Lactobacilli levels following probiotic cheese consumption in adults: A double blind randomized clinical trial. *J Med Res Sci* 2012;17(1): 57-66.
20. Guo L. Salivary biomarkers for caries risk assessment. *J Calif Dent Assoc* 2013;41(2): 107-18.
 21. Houte JV. Role of micro-organisms in caries etiology. *J Dent Res* 1994;73(3): 672-81.
 22. Gondivkar SM, Gadbaile AR, Gondivkar RS, Sarode SC, Sarode GS, Patil S, Awan KH. Nutrition and oral health. *Dis Mon* 2019;65(6):147-154.
 23. Ali S, Farooq I, Al-Thobity AM, et al.: An in-vitro evaluation of fluoride content and enamel remineralization potential of two toothpastes containing different bioactive glasses. *Biomed Mater Eng.* 2019;30(5-6):487-96.
 24. Brandtzaeg P. Secretory immunity with special reference to the oral cavity. *J Oral Microbiol* 2013;5: 1-24.
 25. Suneja ES, Suneja B, Tandon B, Philip NI. An overview of caries risk assessment: Rationale, risk indicators, risk assessment methods, and risk-based caries management protocols. *Indian J Dent Sci* 2017;9(3):210-4.
 26. Axelsson P. The Effect of a Needs-Related Caries Preventive Program in Children and Young Adults – Results after 20 Years. *BMC Oral Health* 2006;6(Suppl 1): 1-9.
 27. Houte JV. Microbiological predictors of caries risk. *Adv Dent Res* 1993;7(2): 87-96.
 28. Hildebrandt GH, Bretz WA. Comparison of culture media and chairside assays for enumerating mutans streptococci. *J Appl Microbiol* 2006;100(6): 1339-47.
 29. Anderson M. Risk assessment and epidemiology of dental caries: review of the literature. *Pediatr Dent.* 2002;24: 377-85.
 30. Jensen B, Bratthall D. A new method for the estimation of mutans streptococci in human saliva. *J Dent Res* 1989;68(3): 468-71.
 31. Roshan NM, Shigli AL, Deshpande SD. Microbiological evaluation of salivary *Streptococcus mutans* from children of age 5-7 years, pre- and post-atraumatic restorative treatment. *Contemp Clin Dent* 2010;1(2): 94-97.
 32. Badet C, Thebaud NB. Ecology of lactobacilli in the oral cavity: A review of literature. *Open Microbiol J* 2008;2: 38-48.
 33. Priya YK, Prathibha MK. Methods of collection of saliva- A review. *Int J Oral Health Dent* 2017;3(3): 149-53.
 34. Ericson D, Bratthall D. Simplified method to estimate salivary buffer capacity. *Scand J Dent Res* 1989;97(5): 405-7.
 35. Turner RJ, Sugiya H. Understanding salivary fluid and protein secretion. *Oral Dis* 2002;8:3-11.
 36. Nemmarugommula N, Arun A, Mythri H. Caries activity tests. *Res Rev: J Dent Sci* 2013;1(3): 50-59.

SURFACE TREATMENT OF INDIRECT RESTORATIONS – A REVIEW

Authors:

Abijith R.S.¹
Leelu J Puthumana²
Prasanth Dhanapal³
Mohammed Sagir⁴
Biju P Babu⁵
Kennet J Chirayath⁶

^{1,2}Post Graduate Student
^{3,5,6}Professor

⁴Head of the Department

Corresponding Author:
Dr. Leelu J Puthumana
Royal Dental College
Iron Hills, Chalissey,
Royal Dental College Rd,
Mannaraparambu,
Palakkad, Kerala 679536

Email id:
leeluputhu94@gmail.com
Ph no: 8547188916

ABSTRACT

The ultimate goal of restorative dentist is to get long lasting restoration for which attaining good bond strength is paramount, for which a thorough understanding of intaglio surface, its surface treatment, resin cements and adhesive system is crucial. Commonly used aesthetic restorative materials involve composites and ceramics, for the context of this particular article we will be focussing on indirect ceramic aesthetic restoration which include metal ceramic restoration, silica-based ceramic and high strength ceramic restorations.

J Ind Dent Assoc Kochi 2022;4(3):19-23.

INTRODUCTION

Modern era of aesthetic dentistry comprises of a combination of adhesion and aesthetics which could be termed as “adhesthetics”¹. The evolution of acid etchable ceramics during 1980s have made significant progress in aesthetics as well as conservative dentistry, that has improved tooth conservation, clinical longevity and ultimate patient and dentist satisfaction². Within this context, ceramic laminate veneers and ceramic crowns have been widely used for cosmetic procedures involving the anterior teeth due to the excellent esthetics, durability, and biocompatibility that characterize these materials³.

The ultimate goal of restorative dentist is to get long lasting restoration for which attaining good bond strength is paramount, for which a thorough understanding of intaglio surface, its surface treatment, resin cements and adhesive system is crucial.

Commonly used aesthetic restorative materials involve composites and ceramics, for the context of this particular article we will be focusing on indirect ceramic aesthetic restoration which include metal ceramic restoration, silica-based ceramic and high strength ceramic restorations.

Metal Ceramic Crown

Metal ceramic restoration could be characterized as traditional restoration which requires the implementation of preparatory features like resistance form and retention form. Along with this proper selection of cement and surface treatment enhance the bond between restorative and tooth interface⁴.

Commonly used cements for metal based restoration include zinc phosphate and glass ionomer cement. However, these conventionally used cements possess the disadvantages of greater stiffness and increased solubility which decreases the bond strength over a period of time hence the focus has been shifted to resin based luting cement⁵. Self-adhesive resin cements offer high fracture strength, adequate bond to the dental structure and low solubility when exposed to oral fluids⁶.

Surface Treatment for Metal Ceramic Restoration

- Clean the intaglio surface using ultrasonics in water for at least 5 min.
- Air abrades using alumina particles (30 to 50 µm pressure: 0.5 to 2.5 bar, approximately 15 s for an area of 10 mm).
- Apply one coat of silane coupling agent on the intaglio surface.
- Never touch the silica-coated intaglio surface with fingers.
- Do not photopolymerize.
- Apply the resin-based luting cement on the intaglio surface and position the restoration carefully on the preparation.
- Allow the cement to flow by slightly rocking the restoration. Seat the restoration and tack-cure any cement excess for approximately 2 seconds using a curing light.
- After removing the excess cement, coat the margins with glycerin gel for oxygen inhibition, and photopolymerize again (20 sec)^{7,8}.

High Strength Ceramic Restorations

When preparation designs are retentive, non-adhesive cements (ie, glass ionomer cements) or moderately adhesive cements (ie, self-adhesive resin cements) can be used successfully to retain these non-silica-based restorations⁹. Whereas in case of silica based restoration like lithium disilicate and high strength restorations like zirconia sophisticated surface treatment is carried out before cementation¹⁰. Recently, several studies have reported that high strength alumina- and zirconia-based dental ceramics cannot be etched with hydrofluoric acid because of their high crystalline phase content^{11,12,13,14}.

Surface Treatment Protocols For High-Strength Ceramics (Ie, Aluminum And Zirconium Oxide) Include 2 Methods.

A) Air-particle abrasion with small aluminum oxide particles (eg, 30 µm).

Followed by application of a primer (contains phosphonate or phosphate monomers) and resin. Phosphate monomers form covalent

bonds with the zirconia surface and have polymerizable resin terminal ends that copolymerize with the resin cements (APC technique).^{15,16,17}

B) Secondly a laboratory technique, namely the internal (INT) coating technique, where the internal surface of the zirconia restoration is thinly coated by fusing silica-based ceramic. In this technique, the internal surface of zirconia frame is modified with silica-based ceramic; therefore, the bonding of resin cement to zirconia ceramic may be improved via silane coupling agents.

Silica-based Ceramic Restorations

Among the all restoration we have discussed so far silica based ceramic (lithium disilicate) restorations give superior aesthetics and tooth conservation¹⁸.

To get predictable and long lasting restorations surface treatment for tooth as well as restoration and strict bonding protocols has to be followed.

Surface Treatment for Intaglio Surface of Restoration

- Surface treatment of intaglio surface using

9.5% hydrofluoric acid (HF) for 20 seconds – HF attacks the glassy phase of the ceramic material, dissolving the surface and exposing the silicate crystals in the matrix, creates surface roughness and the application time depends on the crystalline content of the specific ceramic substrate. A higher crystalline content requires less time for acid etching and less acid concentration.

- Rinse for 1 minute.
- Application of silane coupling agents (1minute) - provides a chemical covalent bonding between the silica in the ceramic matrix and copolymerizes with the methacrylate groups through siloxane bonds. It is important not to place an excess or thick layer of silane because additional layers of hydrolyzed silane will not bond to the porcelain surface and can result in a less than optimal porcelain bond^{19,20}. (Figure I:A-I)

Surface Treatment of Tooth Structure

- Proper isolation of tooth structure.
- Etch the enamel with 37% phosphoric acid gel (enamel 30-40 sec, dentin 10-15 sec).
- Thoroughly rinse with water.

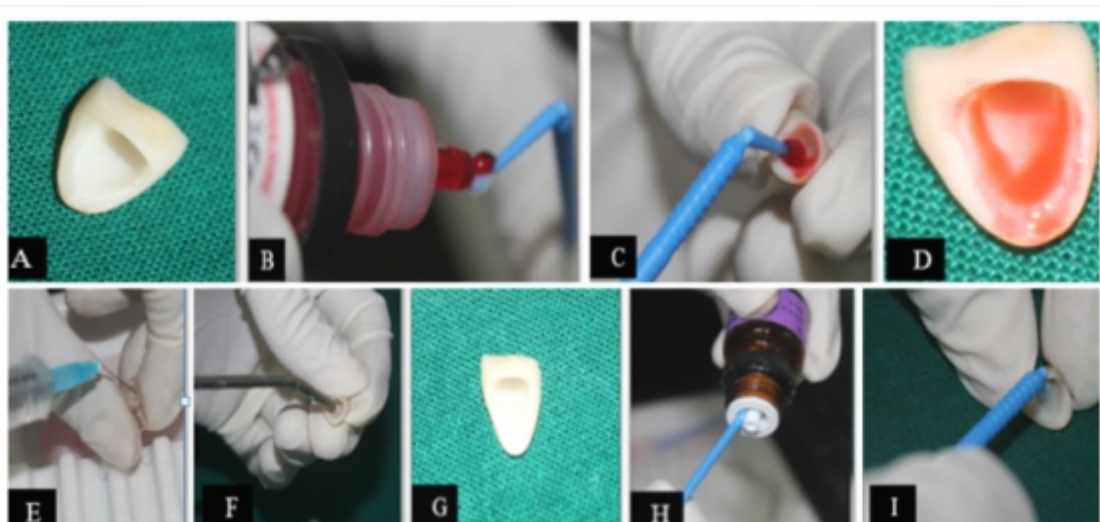

Figure I : A) Intaglio surface of lithium disilicate crown. B&C) Application of 9.5% hydrofluoric acid (HF) for 20 seconds D) Hydrofluoric acid in the intaglio surface E) Saline rinsing F) Air drying G) Dried intaglio surface ready for bonding . H&I) Application of silane coupling agents (Photo Courtesy-Dr. Prasanth Dhanapal)

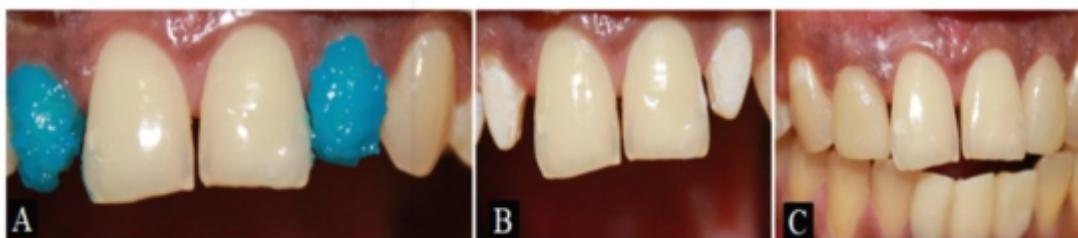


Figure II A) Etching of the tooth with 37% phosphoric acid gel B) Drying the tooth surface C) After bonding (Photo Courtesy – Dr.Prasanth Dhanapal)

- Apply bonding agent and light-cure it (20) sec. (Figure II :A-C)

CONCLUSION

The intaglio surface of the restoration where the power actually lies is always ignored, not understood or not aware of them. Making sure that the intaglio surface is prepared and treated appropriately is crucial for the clinical longevity of the indirect restoration. Optimizing intaglio surface requires an understanding involved substrate and material as well as logical and systematic methodology in their manipulation.

REFERENCES

1. Ferraris F. Posterior indirect adhesive restorations (PIAR): preparation designs and adhesthetics clinical protocol. *Int J Esthet Dent*. 2017 Jan 1;12(4):482-502.
2. Cardenas AM, Siqueira F, Hass V, Malaquias P, Gutierrez MF, Reis A, Perdigão J, Loguercio A. Effect of MDP-containing silane and adhesive used alone or in combination on the long-term bond strength and chemical interaction with lithium disilicate ceramics. *J Adhes Dent*. 2017 Jan 1;19(3):203-12.
3. Soares CJ, Soares PV, Pereira JC, Fonseca RB. Surface treatment protocols in the cementation process of ceramic and laboratory-processed composite restorations: a literature review. *Journal of esthetic and restorative dentistry*. 2005 Jul;17(4):224-35.
4. Cobb DS, Vargas MA, Fridrich TA, Bouschlicher MR. Metal surface treatment: Characterization and effect on composite to metal bond strength. *Oper Dent* 2000;25:427-33.
5. O'Connor RP, Nayyar A, Kovarik RE. Effect of internal microblasting on retention of cemented cast crowns. *J Prosthet Dent*. 1990;64:557-562.
6. Kapoor S, Prabhu N, Balakrishnan D. Comparison of the effect of different surface treatments on the bond strength of different cements with nickel chromium metal alloy: An in vitro study. *Journal of clinical and experimental dentistry*. 2017 Jul;9(7):e912.
7. Al-Helou H, Swed E. Effect of metal type and surface treatment on shear bond strength of resin cement (in vitro study). *The Journal of the Indian Prosthodontic Society*. 2016 Jan;16(1):49.
8. Kitayama S, Nikaido T, Ikeda M, Alireza S, Miura H, Tagami J. Internal coating of zirconia restoration with silica-based ceramic improves bonding of resin cement to dental zirconia ceramic. *Bio-medical materials and engineering*. 2010 Jan 1;20(2):77-87.
9. Suh BI, Chen L, Brown DJ. Bonding to zirconia: innovation in adhesion. *Compend Contin Educ Dent*. 2010;31(special issue 1):2-7
10. Mattiello RD, Coelho TM, Insaurralde E, Coelho AA, Terra GP, Kasuya AV, Favarão IN, Gonçalves LD, Fonseca RB. A review of surface treatment methods to improve the adhesive cementation of zirconia-based

ceramics. International Scholarly Research Notices. 2013;2013.

11. Menezes FCH, Borges GA, Valentino TA, Oliveira MAHM, Turssi CP, Correr-sobrinho L. Effect of surface treatment and storage on the bond strength of different ceramic systems. *Braz J Oral Sci* 2009; 8: 119-123. 37)
12. Derand P, Derand T. Bond strength of luting cements to zirconium oxide ceramics. *Int J Prosthodont* 2000; 13: 131-135. 38)
13. Della Bona A, Borba M, Benetti P, Cecchetti D. Effect of surface treatments on the bond strength of a zirconia-reinforced ceramic to composite resin. *Braz Oral Res* 2007; 21: 10-15. 39)
14. Aboushelib MN, Matinlinna JP, Salameh Z, Ounsi H. Innovations in bonding to zirconia-based materials: Part I. *Dent Mater* 2008; 24: 1268-1272.
15. Melo RM, Souza RO, Dursun E, Monteiro EB, Valandro LF, Bottino MA. Surface treatments of zirconia to enhance bonding durability. *Operative dentistry*. 2015 Nov;40(6):636-43.
16. Blatz MB. Cementation of porcelain restorations. *Prac Proced Aesthet Dent*. 2002;14:616
17. Bottino MA, Valandro LF, Scotti R, et al. Effect of surface treatments on the resin bond to zirconium-based ceramic. *Int J Prosthodont*. 2005;18:60-65.
18. Thurmond JW, Barkmeier WW, Wilwerding TM. Effect of porcelain surface treatments on bond strengths of composite resin bonded to porcelain. *J Prosthet Dent*. 1994;72:355-359.
19. Blatz MB, Chiche G, Holst S, et al. Influence of surface treatment and simulated aging on bond strengths of luting agents to zirconia. *Quintessence Int*. 2007;38:745-753.
20. Empress II IP, Press EM. Eleven-year retrospective survival study of 275 veneered lithium disilicate single crowns. *Int J Periodontics Restorative Dent*. 2015;35:685-94.

CONSERVATIVE BRIDGES - AN UNEXPLORED TREATMENT OPTION

ABSTRACT

Conservative bridges are a minimally invasive treatment option for replacing missing teeth. When compared to conventional bridges that causes pulpal trauma and bone resorption, they require minimal tooth preparation and are ideal for both young and geriatric patients. Since their introduction in the early 1970s, they have undergone various changes in their method of retention and materials used in their construction. Perceptive patient selection with ideal execution of clinical procedures will ensure long lasting clinical outcome when one or possibly two teeth are to be replaced. This review article details the history, advantages, indications, survival, and designs of resin-retained bridges.

Author:

¹Jewel Mary Jose

²Prasanth Dhanapal

³Mohammed Sagir

⁴Biju P Babu

⁵Jojo Kottoor

⁶Jayakanth K

¹Post Graduate Student

^{2,4,5}Professor

⁶Reader

Department of Conservative
Dentistry and Endodontics
Royal Dental College
Chalissery, Palakkad

J Ind Dent Assoc Kochi 2022;4(3):24-8.

INTRODUCTION

Various treatment options are available for the replacement of the missing teeth such as implant, removable partial denture, and fixed partial denture. Removable partial denture may cause bone resorption and flattening of the interdental papillae in the long term. Conventional bridges require adequate amount of tooth preparation of all the surfaces of the abutment tooth which may lead to pulpal trauma and hypersensitivity in young adult patients. In teeth with large pulp chambers and insufficient enamel, a more conservative and less invasive resin bonded prosthesis may be an alternative treatment to replace the missing tooth as well as to preserve the remaining tooth structure.¹

In 1973, Rochette pioneered the use of a perforated type IV gold cast alloy framework with acid etch composite for periodontal splinting of anterior teeth². In 1977, Howe and Denehy described a technique for the fabrication and attachment of an anterior fixed partial denture (FPD) to the lingual surface of abutment teeth using composite resin and acid-etch enamel³. In 1980, the first resin bonded bridge utilizing a framework for the replacement of posterior teeth was described by Lividitis⁴. Since then there has been tremendous development in surface treatments, enamel and dentine bonding

agents and resin cements, thus increasing the popularity of conservative bridges.

INDICATIONS

- The ideal site for a conservative bridge is where the edentulous space is no wider than one or two teeth.⁵
- In young patients, because the teeth usually have large pulp chambers and short clinical crowns.
- Older patients with gingival recession and mobile teeth because splinting can be incorporated with the bridge.
- Un-restored/minimally restored teeth⁶.

CONTRAINDICATIONS

- Insufficient tooth enamel.⁷
- If the abutment teeth has very high mobility and has large restorations.
- Excessive occlusal loading. Debonding may occur when occlusal contacts are present on the pontics in excursive movements.⁸
- Difficulty in isolation for cementation to achieve a dry field.⁹

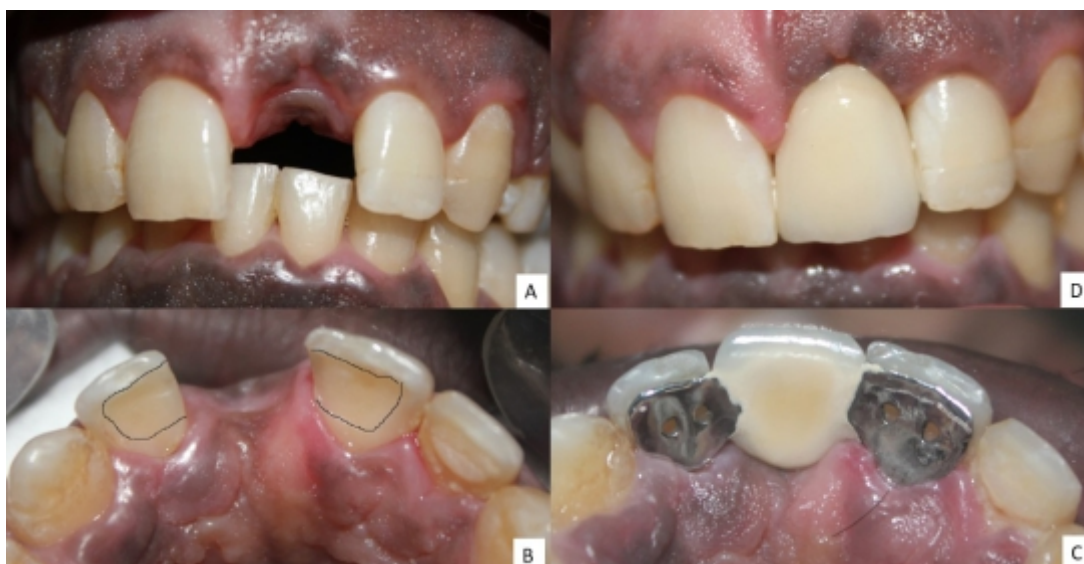

Illustration of stepwise fabrication of Maryland bridge for missing 21

- A) preoperative photograph B) outline for final preparation C) lingual view
D) facial view of conservative bridge (Photo Courtesy - Dr. Prasanth Dhanapal)

CLASSIFICATION

Conservative bridges are classified according to the type of pontic: A. Natural Tooth Pontic; The crowns of natural teeth (primarily incisors) often can be used as acid-etched, resin-bonded pontics.¹⁰

Indications

- Periodontally involved teeth that warrant extraction.
- Teeth with fractured roots
- Teeth that are unsuccessfully reimplanted after avulsion.
- Teeth with unsuccessful root canal treatment.

B. Denture Tooth Pontic; An acrylic resin denture tooth can be used as a pontic for the replacement of missing maxillary or mandibular incisors by using the acid etch-resin bonding technique(11). This type of bridge is sometimes used as an interim prosthesis and is called a temporary bridge, it can be a viable alternative to a conventional bridge.

C. Pontic, Either Of Porcelain-Fused-To-Metal Pontic Or All-Metal Pontic With Metal Retainers;

A stronger and more permanent type of acid-etched, resin-bonded bridge is possible by use of a cast metal framework. In anterior areas where esthetics is a consideration, the design of the bridge includes a porcelain fused-to-metal pontic with metal winged retainers extending mesially and distally for attachment to the proximal and lingual surfaces of the abutment teeth. In posterior areas where esthetics is not a critical factor, the bridge can have either a porcelain-fused-to-metal or an all-metal pontic.

Types of Resin-Bonded Bridges with Metal Retainers

1. Rochette Bridges

This type uses small countersunk perforations in the retainer sections for retention and is best suited for anterior bridges. The perforations should be approximately 1.5 to 2 mm apart and have a maximum diameter of 1.5 mm on the tooth side. Each hole is countersunk so that the widest diameter is toward the outside of the retainer. When the bridge is bonded with a bonding medium, it is mechanically locked in place by microscopic undercuts in the etched enamel and the countersunk holes in the retainer.

2. Maryland Bridges

Instead of perforations, the tooth side of the

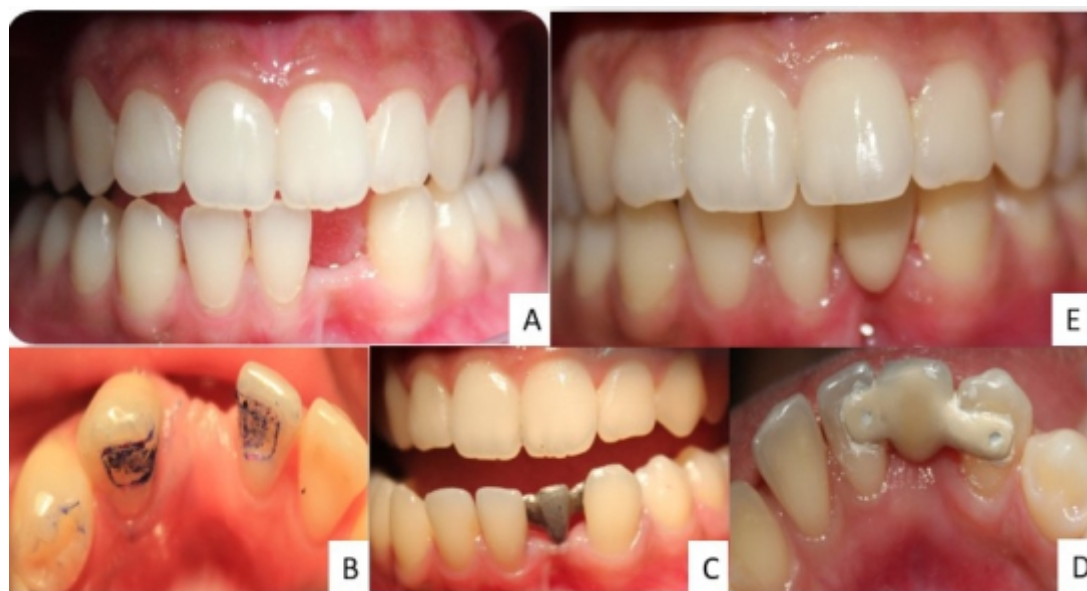

Illustration of stepwise fabrication of Maryland bridge for missing 31 A)preoperative photograph B)outline for final preparation C)metal coping D)lingual view E)facial view of resin bonded bridge (Photo Courtesy – Dr.Prasanth Dhanapal)

metal framework is electrolytically or chemically etched, which produces microscopic undercuts. The bridge is attached with a self-cured, resin-bonding medium that locks into the microscopic undercuts of both the etched retainer and the etched enamel. It can be used for both anterior and posterior bridges. Recently, Maryland bridges are fabricated with no electrolytic etching of the surface and chemically bonded to the tooth by a process called silicoating¹². 4-META or phosphate ester-containing, resin bonding medium that is capable of strongly bonding to metal surfaces can also be used.¹³ These types of Maryland bridges are referred to as adhesion bridges.

D. All-Porcelain Pontics: Improvements in dental porcelains along with the capacity to etch and bond strongly to porcelain surface have made all-porcelain pontics a viable alternative to pontics with metal, "winged" retainers.¹⁴ They are indicated when the tooth anatomy precludes or restricts the preparation and placement of a metal, in adolescents and young adults with virgin unrestored teeth due to less invasive preparation. In young patients all-porcelain pontics can also be placed as interim restorations until implants or a more permanent prosthesis can be done at an older age. They are contraindicated if the abutment teeth have no intact proximal enamel surfaces, contain large composite restorations or if they are unstable due to high mobility.

Fibre Reinforced Composite Resin Bridges

These bridges are adhesive, minimally invasive, and economic single unit restorations that can be used for single visit replacement of a missing tooth. Ribbond is a bondable, polyethylene, lock-stitch multidirectional reinforcement ribbon for composite resin.¹⁵ It has been reported that the lock-stitch weave of Ribbond is easier for the clinician to manipulate, increase flexural strength and flexural modulus of composite resins and resists cracking.

Predictability of Survival Rate

Based on statistical analysis, the predicted survival rate for 5 years and 10 years are 83.6% and 64.9% respectively.¹⁶ Retention of RBB in

maxilla when compared to mandible is 1.774. 77% of the complications were due to debond of RBBs and 13% were due to porcelain fracture. Parafunctional habits might increase the risk of failure of restorations. Silicoating has been reported to show better retention than other surface treatments¹⁷.

CONCLUSION

Conservative bridges can be considered as minimally invasive, reversible, aesthetic, and predictable restorations for fixed replacement of missing teeth. These can be ideal restorations for fixed replacement of teeth if good survival rates can be achieved. Proper patient selection, treatment planning will help to fabricate successful restorations with longer survival rate.

REFERENCES

1. Lividitis G. J. (1980) Cast metal resin-bonded retainers for posterior teeth. J. Am Dent. Assoc. 101,926-929.
2. Rochette AL. Attachment of a splint to enamel of lower anterior teeth. J Prosthet Dent 1973;30:418-23.
3. Howe D F, Denehy G E. Anterior fixed partial dentures utilizing the acid-etch technique and a cast metal framework. J Prosthet Dent 1977; 37: 28-31.
4. Edelhoff D, Sorensen J A. Tooth structure removal associated with various preparation designs for anterior teeth. J Prosthet Dent 2002; 87: 503-509.
5. Ritter AV. Sturdevant's art & science of operative dentistry-e-book. Elsevier Health Sciences; 2017 Dec 20
6. George G, Hemmings K, Patel K. Resin-retained bridges re-visited part 1. history and indications. Primary Dental Care. 2002 Jul 1;9(3):87-91
7. Creugers NH. Resin-retained bridges in the treatment of traumatized dentition. Dental Traumatology. 1993 Apr;9(2):53
8. Durey KA, Nixon PJ, Robinson S, Chan MY. Resin bonded bridges: techniques for success. British dental journal. 2011 Aug;211(3):113-8

9. Balasubramaniam GR. Predictability of resin bonded bridges—a systematic review. *British Dental Journal*. 2017 Jun;222(11):849-58.
10. Ibsen RL. Fixed prosthetics with a natural crown pontic using an adhesive composite. Case history. *J South Calif Dent Assoc* 1973;41:100-2
11. Stolpa J. B. (1975) An adhesive technique for small anterior fixed partial dentures. *J. Prosthet. Dent*. 34,5 13-5 19
12. Musil R, Tiller HJ. The Adhesion of Dental Resins to Metal Surfaces. The KulzerSilicoater Technique. Wehrein: Kulzer &GmbH, 1984
13. Cooley RL, Burger KM, Chain MC: Evaluation of a 4-META adhesive cement, *J Esthet Dent* 3(1):7, 1991
14. Moore DL et al: Retentive strength of anterior etched porcelain bridges attached with composite resin: an in vitro comparison.
15. Strassler HE, Taler D, Sensi L. Single visit natural tooth pontic bridge with fiber reinforcement ribbon. *Oral Health*. 2007 Jul;97(7):24.
16. Pjetursson B E, Tan W C, Tan K, Brägger U, Zwahlen M, Lang N P. A systematic review of the survival and complication rates of resin-bonded bridges after an observation period of at least 5 years. *Clin Oral Implants Res* 2002; 19: 131–141
17. De kanter R J, Creugers N H, Verzijden C W, Vant hof M A. Five-year multi-practice clinical study on posterior resin-bonded bridges. *J Dent Res* 1998; 77: 609–614

NON-VITAL BLEACHING TECHNIQUE OF DISCOLOURED TOOTH: A NARRATIVE REVIEW

Author:

Akthar Ramees M K¹
Prasanth Dhanapal²
Mohammed Sagir³
Kennet J Chirayath⁴
S Maneesh Ahamed⁵
Kripa T⁶

Post Graduate Student¹
Professor^{2,4}
Head Of The Department³
Assistant Professor^{5,6}

Department of Conservative
Dentistry and Endodontics
Royal Dental College
Chalissery, Palakkad

ABSTRACT

Today, the bleaching of nonvital, discoloured teeth is a low-risk routine treatment for improving aesthetics. Depending on the situation, the walking bleach technique can be an uncomplicated, minimally invasive and convenient treatment modality for both patients and dentists. This review article focuses on the aetiology of tooth discolorations, different treatment techniques of non-vital bleaching, indications, contraindications of bleaching procedures, procedural steps of walking bleaching in detail and adverse effects.

J Ind Dent Assoc Kochi 2022;4(3):29-34.

INTRODUCTION

In modern society there is a growing concern for beauty and perfect looks than ever before. In particular, the “perfect smile” has gained popularity, including the light-colored teeth. Vital tooth bleaching aims to lighten the entire arch while nonvital bleaching procedures are used to treat discolored teeth as they blend in with the adjacent teeth. Intracoronal bleaching, also known as non-vital bleaching, has been around since 1848¹, when chloride of lime was placed inside the pulp chamber and used as an oxidizing agent. Since then, bleaching techniques for the management of the discolored tooth have evolved to increase safety and predictability.

ETIOLOGY OF TEETH DISCOLOURATION

Tooth discoloration can be induced by intrinsic stains incorporated in tooth structures and extrinsic stains deposited on tooth surfaces. This can be due to patient- or dentist-related causes². Correct diagnosis of the etiology of discoloration is important for treatment planning and outcome assessment.

Common causes are listed below:

- a) Intrapulpal hemorrhage following trauma, where blood enters the dentinal tubules and decomposes resulting in deposition of chromogenic blood degradation products, such as hemosiderin, hemin, hematin and haematoidin.
- b) Pulpal necrosis leading to chromogenic degradation products
- c) Root canal cement or gutta percha remaining in the coronal portion of the pulp chamber
- d) Failure to completely remove the pulp and pulp horns
- e) Combining sodium hypochlorite, even at low concentrations, and chlorhexidine during irrigation, may result in formation of brownish-red precipitate
- f) Dental caries
- g) Failing or leaking coronal restorations

- h) Cervical resorption
- i) Calcific metamorphosis
- j) Enamel hypoplasia/ hypomineralisation defects resulting from disturbances to the developing tooth germ
- k) Malaligned /inward placed tooth which due to an increased susceptibility to extrinsic staining and shadowing, may appear discoloured.³

INDICATIONS FOR BLEACHING

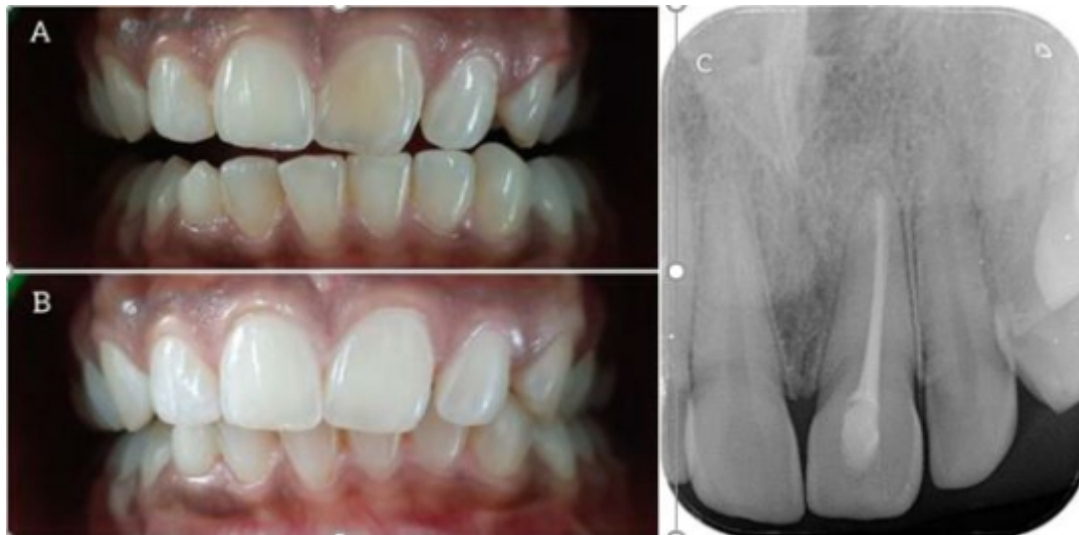1. Discolorations of pulp chamber origin
2. Dentine discolourations⁴
3. Discolorations resulting from calcific metamorphosis
4. Enamel hypoplasia/ hypomineralisation.³

CONTRAINDICATIONS FOR BLEACHING

1. Pregnancy and breastfeeding
2. Patients with unrealistic expectations regarding the aesthetic outcome
3. Patients exhibiting or with a history of extreme dental sensitivity
4. Insufficient coronal tooth tissue to allow sealing of bleaching material inside the pulp chamber
5. Teeth with deep surface cracks and fracture lines
6. Existing crowns or large restorations in the aesthetic smile zone
7. Teeth with caries and periapical lesions
8. Symptomatic teeth.³

Non-vital Bleaching

Bleaching is a treatment modality involving an oxidative chemical that modifies the light-absorbing and/or light- reflecting nature of a material structure, thereby increasing its perception of whiteness. In-office tooth bleaching using peroxide compounds has been practiced in dentistry for more than a century. Intra-coronal bleaching of endodontically treated teeth may be successfully carried out



1. Figure 1 A) A labial view demonstrating a discolored non-vital upper left central incisor, upon clinical and radiographic examination, incompletely obturated tooth with a persistent periapical lesion was observed. Pain and lesion subsided after re root canal treatment. Postoperatively in two months, nonvital bleaching was planned on the tooth with sodium perborate dihydrate powder; B) Labial view showing the tooth post-two weeks of intracoronal walking bleaching procedure and the desired outcome was obtained C) Post-operative radiograph of the discolored tooth.

with satisfying long-term esthetic results (Figure 1). A successful outcome depends mainly on the etiology, correct diagnosis, and proper selection of bleaching technique²⁵⁶. The methods most commonly employed to bleach endodontically treated teeth are the “walking bleach” and the thermocatalytic techniques.

INITIAL CONSIDERATIONS

A detailed history, especially relating to the discolored tooth, is crucial to aid in the diagnosis of etiology of discolorations. Followed by a comprehensive extraoral and intraoral examination is required. The color and presentation of the discolorations may aid in the diagnosis. A comprehensive aesthetic evaluation must be undertaken. This must include an initial shade evaluation.

A good quality periapical radiograph is also required in cases of discoloration resulting from trauma, pulp necrosis or previous endodontic or root canal treatment. Radiographic assessment of previous

endodontic treatment should also be used to aid in the assessment of the need for secondary endodontic treatment before bleaching. Prior to undertaking bleaching, existing carious lesions, periodontal disease and periapical pathology should be managed, as bleaching treatment can exacerbate existing periapical lesions.

Intraoral photography is also very useful when undertaking bleaching treatment. A labial view with a shade tab correlating to the darkest tooth, placed in the region of the canine is crucial and allows vital comparisons for the progression of bleaching treatment.

Walking Bleach Technique

In the early 1960s, several dentists realized that utilizing the pulp space in non-vital teeth for the placement of a bleaching agent could be advantageous. In 1961, Spasser⁷ described a method of sealing in a mixture of sodium perborate with water into the pulp chamber and leaving it for a week. Nutting and Poe⁸ described a modification of the technique in

1963, whereby Sodium Perborate and Hydrogen Peroxide were sealed into the tooth and used synergistically to bleach the tooth

In the walking bleach techniques, following barrier preparation the bleaching agent is placed into the tooth over the barrier. The tooth is sealed with an appropriate palatal restoration. The patient is evaluated on a two-weekly basis and the procedure is repeated as appropriate until the desired shade has been achieved.

Procedural Steps

Explain the patient with the possible causes of dis-coloration, the procedure to be followed, the expected outcome, and the possibility of future rediscoloration. Radiographically assess the status of the periapical tissues and the quality of endodontic obturation. Endodontic failure or questionable obturation should be retreated prior to bleaching.

Assess the quality and shade of any restoration present and replace if it is defective. Tooth discoloration is frequently the result of leaking or discolored restorations. In such cases, cleaning the pulp chamber and replacing the defective restorations should be done. Evaluate tooth color with a shade guide and, if possible, take clinical photographs at the beginning of and throughout the procedure. These provide a

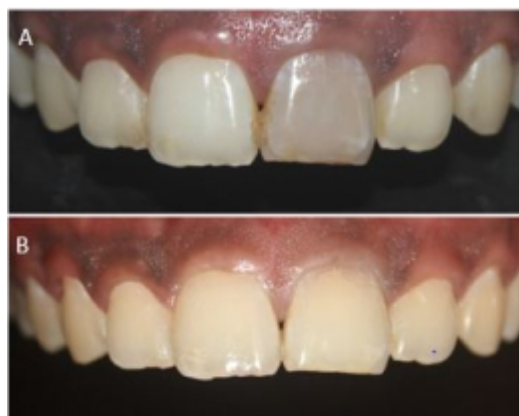

Figure 2

Intracoronary bleaching of tooth discoloration due to pulp necrosis in a maxillary left central incisor A) Pre-treatment photograph. B). After 4 weeks of walking bleach with sodium perborate, the tooth regained its original shade. (courtesy: Dr Abijith R S, Post Graduate, Royal Dental College, Challissery)

point of reference for future comparison. Isolate the tooth with a dental dam. The dam must fit tightly at the cervical margin of the tooth to prevent possible leakage of the bleaching agent onto the gingival tissue. Interproximal wedges and ligatures may also be used for better isolation.

Remove all restorative materials from the access cavity, expose the dentin, and refine the access. Verify that the pulp horns and other areas containing the pulp tissue are clean. Remove all materials to a level just below the labial gingival margin. Orange solvent, chloroform, or xylene on a cotton pellet may be used to completely dissolve sealer remnants to cover the endodontic obturation, apply a sufficiently thick layer, at least 2 mm, of a protective white cement barrier, such as polycarboxylate cement, zinc phosphate cement, glass ionomer, intermediate restorative material (IRM), white colored MTA. The coronal height of the barrier should protect the dentinal tubules and conform to the external epithelial attachment.⁹ Prepare the walking bleach paste by mixing sodium perborate and an inert liquid, such as water, saline, or anesthetic solution, to a thick consistency of wet sand. Although sodium perborate plus 30% H₂O₂ mixture may bleach faster, in most cases, long-term results are similar to those with sodium perborate and water alone and therefore need not to be used routinely.^{10 11 12 13} With a plastic instrument, pack the pulp chamber with the paste. Remove excess liquid by compressing with a cotton pellet. This also compresses and push the paste into all areas of the pulp chamber.

Remove the excess bleaching paste from undercuts in the pulp horn and gingival area and apply a thick well-sealed temporary filling (preferably IRM) straight against the paste and into the undercuts. To ensure a good seal, judiciously pack the temporary filling, at least 3 mm thick. Remove the dental dam and inform the patient that bleaching agents work in a slow manner and significant lightening may not be evident for several days.

Evaluate the patient 2 weeks later and, if necessary, repeat the procedure several times.^{14,12} Repeat treatments are similar to the first one. As an optional procedure, if initial bleaching is not satisfactory, strengthen the

walking bleach paste by mixing sodium perborate with gradually increasing concentrations of H_2O_2 (3% to 30%) instead of water. The more potent oxidizers may have an improved bleaching effect but are not used routinely because of the possibility of permeation into the tubules and damage to the cervical periodontium by these more caustic agents. In such cases, a protective cream, such as Orabase or Vaseline, must be applied to the surrounding gingival tissues prior to dam placement. In most cases, discoloration will improve after one to two treatments. After three consecutive placements if there is no significant improvement, reassess the case for proper diagnosis of the etiology of discoloration and plan the treatment accordingly.

Inside/Outside Open Technique (IOO)

First described by Settembrini et al. in 1997²³, and later modified by Liebenberg et al.²⁴ this technique involves leaving the access cavity open following adequate barrier preparation and the patient directly applying the bleaching agent with a syringe into the access cavity and the bleaching tray. The bleaching tray is then seated into the mouth to cover the access cavity. The bleaching agent is subsequently replaced every 4-6 hours and the patient reviewed at 2-3 days to reassess the degree of lightening of the tooth.

The Inside/Outside Closed Technique (IOC)

This technique, first described by Haywood and DiAngelis in 2010,²⁵ is a modification of the inside/outside technique. The technique involves sealing the bleaching agent into the access cavity following appropriate barrier preparation, and then utilising a 'single tooth' bleaching tray, to apply the bleaching agent from the external surface. A palatal restoration is placed to seal the bleaching agent into the tooth. The bleaching tray is worn overnight until the desired shade is achieved or until the review appointment. Further re-application of the bleaching agent intracoronally can be undertaken at the review appointment, if needed.

Adverse Effects

High concentrations of H_2O_2 are caustic and cause chemical burns and sloughing of the gingiva. When using such solutions, the H_2O_2 concentration should be maintained as low as practically possible and the soft tissues should always be protected with Vaseline, Orabase, or cocoa butter. H_2O_2 at high concentration is not the agent of choice for routine intracoronary bleaching.

Oxygen inhibits resin polymerization; consequently, residual H_2O_2 in tooth structure after bleaching adversely affects the bonding strength of resin composites to enamel and dentin.^{15,16} Scanning electron microscopy (SEM) examination has shown an increase in the resin porosity.¹⁷ This presents a clinical problem when immediate esthetic restoration of the bleached tooth is required. It is therefore recommended that residual H_2O_2 should be totally eliminated prior to the placement of composite.

Clinical reports^{18,19} and histological studies^{22,21,22} have shown that intracoronary bleaching may, under certain conditions, induce external cervical root resorption. This is probably caused by the highly concentrated oxidizing agent used in those cases, particularly 30 to 35% H_2O_2 .

CONCLUSION

Given the appropriate indication, the bleaching of nonvital teeth is a relatively low-risk intervention to improve the esthetics of endodontically treated teeth. Depending on the situation, the walking bleach technique can be an uncomplicated, minimally invasive and convenient treatment modality for both patients and dentists.

In-office bleaching can often only produce short-term success, based largely on the dehydration of the tooth. The risk of root resorption cannot be exactly determined by the available data. The ability to provide treatment with minimal biological side effects continues to make bleaching a first line choice in cases presenting with a single or multiple non-vital discolored tooth.

REFERENCES

1. Dwindle W W: Ninth Annual Meeting of American Society of Dental Surgeons. Article X. *Am J Dent Sci* 1850; 1: 57–61.
2. Rotstein I, Walton RE. Bleaching discolored teeth. In: Torabinejad M, Walton RE, Fouad AF, editors. *Endodontics Principles and Practice*. 5th ed. St. Louis, MI: Elsevier/Saunders; 2015. p. 428.
3. The single discoloured tooth: vital and non-vital bleaching techniques. Joseph Greenwall-Cohen and Linda H. Greenwall
4. Ingle's endodontics 7th ed. Rotstein, John I. Ingle
5. Abbott P, Heah SY. Internal bleaching of teeth: an analysis of 255 teeth. *Aust Dent J*. 2009;54:326–333.
6. Plotino G, Buono L, Grande NM, et al. Nonvital tooth bleaching: a review of the literature and clinical procedures. *J Endod*. 2008;34:394–407.
7. Spasser H F. A simple bleaching technique using sodium perborate. *NYS Dent J* 1961; 27: 332–334.
8. Nutting E B, Poe G S. A new combination for bleaching teeth. *J South Calif Dent Assoc* 1963; 31: 289–291.
9. Steiner DR, West JD. A method to determine the location and shape of an intracoronary bleach barrier. *J Endod*. 1994;20:304–306.
10. Rotstein I, Zalkind M, Mor C, et al. In vitro efficacy of sodium perborate preparations used for intracoronary bleaching of discolored non-vital teeth. *Endod Dent Traumatol*. 1991;7:177–180.
11. Rotstein I, Mor C, Friedman S. Prognosis of intracoronary bleaching with sodium perborate preparations in vitro: 1 year study. *J Endod*. 1993;19:10–12.
12. Holmstrup G, Palm AM, Lambjerg-Hansen H. Bleaching of discoloured root-filled teeth. *Endod Dent Traumatol*. 1988; 4:197–201.
13. Ari H, Ungör M. In vitro comparison of different types of sodium perborate used for intracoronary bleaching of discoloured teeth. *Int Endod J*. 2002;35:433–436.
14. Attin T, Paque F, Ajam F, Lennon AM. Review of the current status of tooth whitening with the walking bleach technique. *Int Endod J*. 2003;36:313–329.
15. Titley KC, Torneck CD, Ruse ND, Krmec D. Adhesion of a resin composite to bleached and unbleached human enamel. *J Endod*. 1993;19:112–115.
16. Attin T, Hannig C, Weigand A, Attin R. Effect of bleaching on restorative materials and restorations a systematic review. *Dent Mater*. 2004;20:852–861.
17. Titley KC, Torneck CD, Smith DC, et al. Scanning electron microscopy observations on the penetration and structure of resin tags in bleached and unbleached bovine enamel. *J Endod*. 1991;17:72–75.
18. Harrington GW, Natkin E. External resorption associated with bleaching of pulpless teeth. *J Endod*. 1979;5:344–348.
19. Shearer GJ. External resorption associated with bleaching of a non-vital tooth. *Aust Endod Newslett*. 1984;10:16–18.
20. Madison S, Walton RE. Cervical root resorption following bleaching of endodontically treated teeth. *J Endod*. 1990; 16:570–574.
21. Rotstein I, Friedman S, Mor C, et al. Histological characterization of bleaching-induced external root resorption in dogs. *J Endod*. 1991;17:436–441.
22. Heller D, Skriber J, Lin LM. Effect of intracoronary bleaching on external cervical root resorption. *J Endod*. 1992;18:145–148.
23. Settembrini L, Gultz J, Kaim J, Scherer W. A technique for bleaching non vital teeth: inside/outside bleaching. *J Am Dent Assoc* 1997; 128: 1283–1284.
24. Liebenberg W H. Intracoronary lightening of discoloured pulpless teeth: a modified walking bleach technique. *Quintessence Int* 1997; 28: 771–777.
25. Haywood V B, DiAngelis A J. Bleaching the single dark tooth. *Inside Dent* 2010; 6: 42–52.



JIDAK

JOURNAL OF INDIAN DENTAL ASSOCIATION - KOCHI